



An innovative procedure for cranial reconstruction as an aid for human identification

Published: November 1, 2022

Copyright: © 2022 Valoriani S., Mannucci P., Borrini M.

This is an open access, peer-reviewed article edited by Archivio per l'Antropologia e la Etnologia (<http://www.antropologiaetnologia.it>) and distributed under the terms of the Creative Commons Attribution License, which permits unrestricted use, distribution, and reproduction in any medium, provided the original author and source are credited.

Data Availability Statement: All relevant data are within the paper.

Funding: This work was funded by Liverpool John Moores University through the award of a PhD fellowship.

SATU VALORIANI¹, PIERO MANNUCCI², MATTEO BORRINI^{1*}

¹*School of Biological and Environmental Sciences, Liverpool John Moores University*

²*Società Italiana di Antropologia ed Etnologia*

*E-mail: m.borrini@ljmu.ac.uk

Abstract. Human remains are frequently recovered fragmented from forensic contexts. Taphonomic factors and peri-mortem trauma can damage human remains recovered from clandestine graves. Therefore, an incomplete or broken skull can represent a challenge to identifying an individual, osteometric analysis, and trauma interpretation. A reconstructive approach is proposed to aid forensic experts in achieving all the information from human remains. This study proposes an innovative method that involves the use of reversible glue to connect the fragments. Non-permanent wax is used to reconstruct the missing parts and stabilize the skull. The reconstruction procedure is divided into three phases: cleaning, reassembling and remodelling. The reassembling is carried out with non-permanent reversible glue. Consequently, if the reconstructed remains do not have enough solidity to undergo a forensic examination, some of the missing anatomical parts can be replaced with reversible wax modelled on the missing bone's shape. The method allows a more comprehensive examination of the whole skull structure for biological profiling of unknown individuals and a better analysis of trauma and injuries. Moreover, Computed Tomography (CT) and radiographic analysis can be better performed on a reconstructed skull; the data obtained can also be a more appropriate background for unidentified persons' facial approximations.

Keywords: forensic anthropology, biological profiling, forensic medicine, human bone curation, restoration, anatomy, skeletal collection.

INTRODUCTION

The state of conservation of human remains is crucial for identification and anthropometric analysis purposes. The physical examination of bones is an essential part of assessing a biological profile from an anthropological perspective (i.e. sex, ancestry, age, stature and possible pathological changes) (Acsádi *et al.*, 1970; Ubelaker and Buikstra, 1994; Ortner, 2003). However, human skeletal material is usually recovered fragmented from forensic and archaeological contexts. The damage of these elements is usually a consequence of taphonomical events or excavation and post-excavation handling (Borrini *et al.*, 2012a). Post-depositional trauma can lead to fractures, especially on the skull, following the soil pressure after the decomposition of soft tissues, and compression due to the collapse of the lid when the individual was interred in a coffin (Pokines and Baker, 2014a). Besides, in forensic cases, it is not unusual that taphonomical damages can be attributed to animal activities and weather when the remains are exposed on the surface (Borrini *et al.*, 2012b).

Further damage to the remains can be caused by recovery or post-excavation activities due to the exposure and the lifting of the skull and postcranial elements. Frequently, buried remains can be accidentally discovered during construction work, farming activities, gardening or digging by pets. If the bone has become more brittle due to the loss of organic content, an impact from a shovel or any other tool can easily lead to a crack on the impact site (Pokines and Baker, 2014b). Once the remains are brought from the field to the laboratory, appropriate handling is crucial to avoid additional fragmentation (Cronyn, 1990). The effects of poor transportation and storage can be another reason for the appearance of fractures. The storage in rigid boxes with inadequate cushioning may result in further damage. All the events mentioned above can lead to the damage of anatomical parts and the loss of information functional to the biological profiling (Pokines and Baker, 2014b).

The authors propose a new method for reassembling Human remains, in particular the skull. Missing and fragmented anatomical areas can lead to instability, making it impossible to carry out anthropometric analysis and, particularly in the forensic context, trauma (Blau, 2017) and burnt remains analysis (Grevin *et al.*, 1998).

The proposed method consists of separated steps to reconstruct cranial elements with reversible B72-paraloid glue, as suggested by the British Association of Biological Anthropology and Osteoarchaeology (BABA0) (2018), and a pigmented wax.

This paper aims to propose a novel approach that aids the preservation of human remains in order to perform biological profiling and the analysis of

trauma in cases of fragmented and highly fragmented cranial and postcranial elements.

MATERIALS AND METHODS

Status quo documentation

Before describing the different steps of the procedure proposed, it is essential to underline how all the activities should be performed only after complete documentation of the remains' status quo. In addition, any sampling for biological and genetic analysis should be collected before additional handling of the remains is carried out. Also, all the procedure that will be proposed should be documented by the operator and should be previously authorised by the authority in charge of the remains (e.g., Prosecutor Office or Heritage Office in case of historical remains).

Cleaning

The preliminary step of the reconstruction is preparing the samples: the fragments need to be cleaned with cold water and a soft brush to remove any soil covering the surface of the bone. The bones are usually recovered in damp soil, which adds weight to the remains, resulting in crushing and breakage. If the cleaning process is not carried out immediately after the excavation, the soil hardens, producing additional damage to the bones (Bowron, 2003). The cleaning procedure is also essential for analysing the remains and enables the exact reconstruction of the skulls, avoiding any error caused by sediment in the fractures (Borrini, 2007).

Anatomical Arrangement

When the skeletal material is dry, additional photographic documentation is carried out. The fragments are first divided by anatomical position (Brothwell, 1981) and then photographed to document the state of preservation of the remains before the reconstruction (Fig. 1). This anatomical arrangement is instrumental in complex structures like the skull, where the operator needs to have easy access to each fragment to evaluate the assembling order. The matching portions of the fractures need to be precisely identified, and the pieces need to be put together in a specific order to avoid that it will be impractical to add the remaining ones when a few pieces have been already fixed.

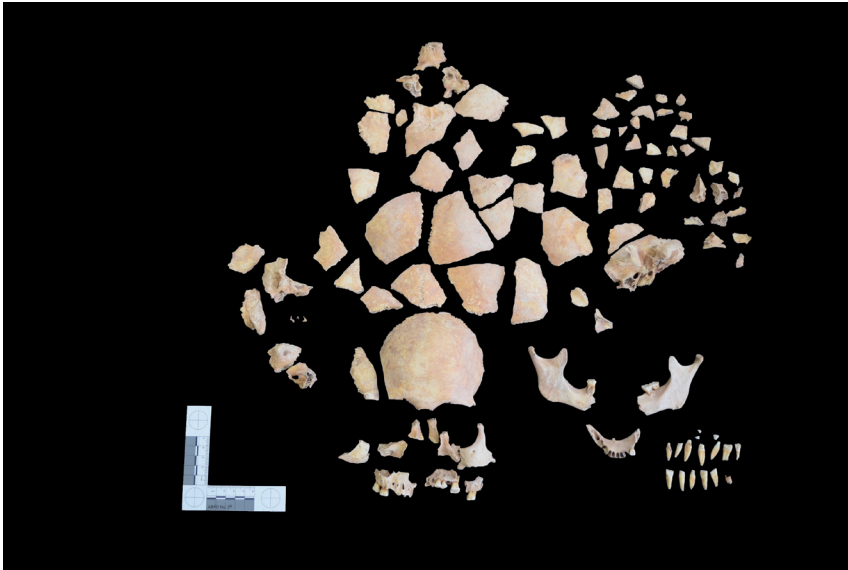


Fig. 1. *Photographic documentation of Skeleton 110 skull from Poulton before reconstruction.*

Reassembling

The reassembling of the fragmented parts is carried out with non-permanent reversible glue. As suggested in the Code of Practice of the British Association of Biological Anthropology and Osteoarchaeology (British Association of Biological Anthropology and Osteoarchaeology, 2018), a solution of HMG Paraloid B-72 (60%) and acetone (40%) is used. Following the previous arrangement for documentation, the reconstruction is first carried out, separating the different anatomical parts. The reconstructed parts are then joined together to recreate the complete element. In case is needed, the reversible glue can be completely removed using acetone, without damaging the specimen.

Frequently, after the recovery, it might be noted that some parts of the skulls are missing due to taphonomical factors. For this reason, the authors proposed a new approach involving the application of wax to fill in the missing parts and give more stability to the sample.

Following the guidelines published by Borrini (Borrini, 2007), the wax is pigmented in order to reproduce bone's natural colour, avoiding a disturbing contrast with the original sample, that could influence the evaluation of the remains, as well as an exact match that could mask the state of preservation of the remains.

The wax

The wax is obtained by mixing several components (Fig. 2), and it is fully reversible. The basic formula of the wax is:

- 20 g of beeswax
- 20 g of paraffin (candle wax)
- 10 g of pine rosin
- 60 g of casting powder
- 60 g of calcium carbonate (limestone flour)

The components are placed in a metallic tray located on a hot plate. First, beeswax and pine rosin need to be melted entirely to avoid the presence of solid residues in the mixture (Fig. 2a). After these materials formed a homogeneous blend, paraffin, casting powder and calcium carbonate are added (Fig. 2b). This admixture creates a compound suitable for reconstructing missing parts in the skull, as it is stable, reversible and does not damage the bone surface. For the best performance in the reconstruction with wax, a mix of pigments (brown iron oxide and raw sienna) can be used to recreate a natural colour. According to the purposes of the restoration, the colour of the reconstructed part can be made more distinguishable from the surrounding bones; however, it is always important that the wax part will not visually outstand, creating a bias during the visual examination of the remains.



Fig. 2a-2b. Wax initial mix made with pine rosin and beeswax (a) and final compound (b).

When the mixture is homogeneous, it is left cooling down at room temperature until it has stiff consistency. The mixture is ready to be used or stored in a dry cold environment. When needed, a piece of wax can be placed on a heated metallic tray to acquire the necessary malleable consistency. The wax will be then modelled on the specimen with a warmed-up spatula.

Reconstruction

After assembling the fragments, the wax can be used to fill gaps if fragments are missing, and their loss can affect the stability of the whole sample.

In skull reconstruction, a layer of tin foil is placed in the cranial vault's inner surface to avoid an excessive accumulation of wax inside; this device will also allow obtaining a reconstructed area with the same thickness as the surrounding bone.

In some cases, wax can help recreate missing anatomical parts, which affects the possibility of putting other portions of the same sample together. This is particularly evident during the reconstruction of skulls, where the splanchnocranium is more fragile than the cranial vault and is characterised by thinner anatomical parts, more prone to taphonomic alterations. Thus, some parts of the face (such as the nasal bones or the zygomatic processes), are recreated to improve the stability of the reconstruction. The result consists of a complete and stable skull that allows the full recording of measurements and trauma and pathology analysis (Fig. 3a and 3b).

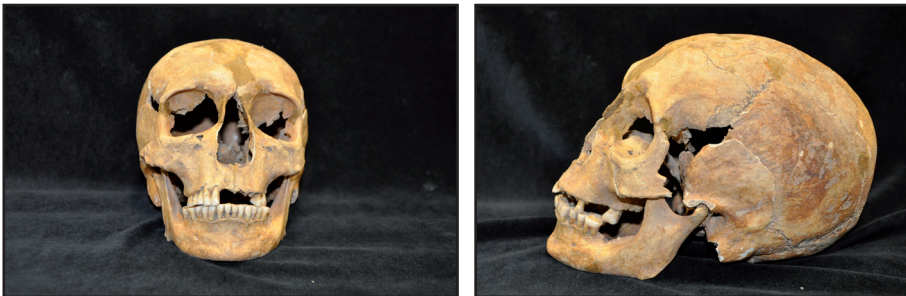

Fig. 3a-3b. Reconstructed skull from Skeleton 155 from Poulton.

RESULTS AND DISCUSSION

Bone reconstruction was very popular in the past, and it is frequent to come across the reassembling of earlier recovered remains. However, some of these early attempts are poor examples, which can be considered more damaging than care for human remains. Those poor results can be related to a lack of anatomical knowledge and training in the curation of skeletal material.

Also, some of the materials used in the past were inadequate (not reversible), leading to the deterioration of many samples. Consequently, in the last years, reconstruction has been abandoned by researchers. With the increase in awareness of appropriate care of human remains, various

recommendations have been published for the treatment and conservation of skeletal material. The main guidelines used in the United Kingdom is the Code of Practice published by BABAO (2018). The code states that «*if a bone is broken, and if appropriate (i.e., for display purposes), it may be joined together using a reversible glue (HMG Paraloid B-72), and the process should be documented*».

Mays, Brickley and Dodwell (2004) instead suggest that only minor reconstruction is worthwhile to enable researchers to record measurements.

Odegaard and Cassman (2006) discuss whether reconstruction is damaging the bone or any other analysis that could be done after the restoration of the sample, suggesting alternative solutions to the use of glue and adhesives. The alternatives include Parafilm M. for long bones and microcrystalline wax strips to fix skull fragments temporarily. The same authors proposed the scanning of the individual skeletal material so that reconstruction could be done virtually and made available for researchers who cannot conduct their research directly on the bones.

The rationale of the solutions mentioned above is avoiding damage to the skeletal materials, which would result in an irreversible loss of information and permanent damage to the bone. Even if the logic of the proposals is understandable, it is important to underline how, in addition to the technical and economic difficulties of the virtual approach, these solutions are not stable, and they do not ensure accuracy in the analysis of a specimen. As suggested in the BABAO code of practice (British Association of Biological Anthropology and Osteoarchaeology, 2018), the first step of the reconstruction involves the use of a 60% solution of B72 mixed with acetone. Once the fragments have been appropriately cleaned from any soil residue and are dried, the remains can be joined together.

The compound used to reconstruct the fragmented elements is suitable for human remains, as it does not affect the integrity of the bone. Differently from other glues used in the past, this solution is reversible with acetone, and it can be removed after the reconstruction if required. If the amalgam is created with the right amount of components and the fragments are placed in a stable position to dry, it will not create a thickness between the fragments, as criticised by Odegaard and Cassman (2006). The solution needs to be liquid enough not to create a layer of solid glue between the bone portions, and its composition needs to be checked frequently, as the acetone tends to evaporate quickly.

Several methods were proposed for human remains digital documentation and reconstruction (e.g., μ CT, laser and SLS) (Silva *et al.*, 2008; Komar *et al.*, 2012; Huotilainen *et al.*, 2014; Gabherr *et al.*, 2016; Errickson *et al.*, 2017; Carew *et al.*, 2019; Collings and Brown, 2020; Lauria *et al.*, 2022). Collings and Brown (2020) compared two 3D imaging methods (μ CT and SLS) to generate virtual

3D models and printing of burnt bones to perform physical fit analysis (PFA) better and avoid excessive handling of human remains. Structured light scanning (SLS) and fused filament deposition (FFD) were advantageous for reproducing fragments for PFA. However, the imaging resolution was not highly accurate and, even if the cost of the technique resulted in being lower than μ CT scanning, it could still be an onerous request for routine cases. Besides, both techniques require a conspicuous amount of time to scan each bone fragment, which can be an obstacle to time constraints. Furthermore, the method does not consider the difficulty represented by missing parts, which is expected due to the fragmentation and post-depositional events (i.e. disturbance of the remains). Huotilainen *et al.* (2014) found the same limitations to accuracy when the same set of data was converted by three different institutions from DICOM to STL file format using their software of reference.

The procedure the authors are proposing with the present paper is not only less time and resources consuming but also offer the possibility to replace the missing parts with a reversible wax. The original compound was invented by the paleoanthropologist Luigi Cardini. After he died in 1971, the wax formula was embraced at the University of Pisa by Francesco Mallegni and introduced to the Florentine University by Vitaliano Rossi (Scarsini and Rossi, personal communications). Since then, the compound has been used, also by Soprintenza laboratories, on remains from archaeological sites. The new formula was designed by Borrini (2007), and the procedures described in the present research have been extensively applied during a PhD project carried out at Liverpool John Moores University to allow the craniometric analysis of 400 skulls from two British medieval sites (Poulton, Cheshire, and Gloucester, Gloucestershire). The cranial reconstruction improved the collection from Gloucester by 69%, reassembling 76 skulls completely fragmented, while the Poulton collection has been improved by 56% (an additional 175 reconstructed skulls have been included). Furthermore, they were largely applied in different scenarios at the University of Florence, allowing the complete reconstruction of skulls from archaeological excavations of different periods (Prehistoric, Etruscan, Medieval, and Historical). The success of these reconstructions has been demonstrated by the publication of the data obtained from the different sites (Borrini and Giachetti, 2012; Borrini *et al.*, 2012c; Borrini *et al.*, 2014a; Borrini *et al.*, 2014b). Also, the reconstruction approach has been applied in forensic cases that have been presented in the Italian court.

The main relevant change to the initial dosage and ingredients originally proposed by Borrini (2007) and detailed in the present article consists of the removal of zinc oxide (ZnO) powder and the introduction of calcium carbonate (CaCO_3). The rationale behind the new formula is to remove the interferences

and radiological artifacts created by ZnO during X-rays and CT scans.

The wax is also mixed with natural pigments to recreate the bone's natural colour. This method does not damage the bone, does not leave any oily residue on the surface and can be easily removed from the specimen using a warmed-up spatula. Final cleaning of the surface where the wax was applied can be performed with methylated spirits (denatured alcohol). It is fundamental that the reconstructed parts are recognisable from the bone, as it needs to be evident that some parts are missing. This is because craniometric measurements and other types of analyses cannot be recorded on a reconstructed area, as the wax is intended to improve the stability of the bone, not recreate the anatomical part. On the other hand, if the reconstruction is not performed, a remarkable amount of data can be lost. It is essential to underline that the reconstruction has to be made by trained anthropologists (Christensen and Sylvester, 2008): to carry it out, excellent knowledge about the human skeleton's anatomy is fundamental. The incorrect placement of fragments during reconstruction not only leads to a false representation of the specimen but also affects future data collection and leads to erroneous results. It is also necessary essential that the conditions of the specimen are assessed before the reconstruction. The restoration of a postmortem warped skull or a severely damaged one by the postmortem events is not recommended as no metric analysis can be carried out. A reconstructive approach of a specimen in genuinely poor condition could be accepted only when a morphological evaluation of trauma is required.

The majority of the skeletal collections usually present less than 50% of complete skulls, thus reducing the analysis potential to only an inadequate part of the samples. This method was also tested in a PhD project involving craniometric analysis (Valoriani, 2019). Many anthropological samples are stored in Universities and represent a valuable resource for students, researchers and lecturers. However, as described before, most collections are fragmentary, which often represents an obstacle to examining the remains, especially if they present trauma or a pathological condition. In the case of cranial reconstruction, a complete collection is highly advantageous for students and researchers to appreciate the variability within a population and analyse the cranial features as a whole.

In addition, the reconstructions of fragmented skeletons can provide information otherwise unavailable for the understating of traumatic death in both forensic and historical cases (Grevin *et al.*, 1998). An example of a successful cranial reconstruction could be represented by Skeleton 1303 from St Owen's cemetery, Gloucester. Valoriani and colleagues (2017) analysed and published the individual as a case study of sharp force trauma in medieval Gloucester. The reconstruction allowed to observe better the sharp force

trauma on the skull and the consequent radiating fractures caused by the impact of a sharp object. As the complete skeleton was reconstructed, a sharp force trauma was also identified on the right scapula, which would not have been possible to locate without restoring the anatomical part (Fig. 4a and 4b).

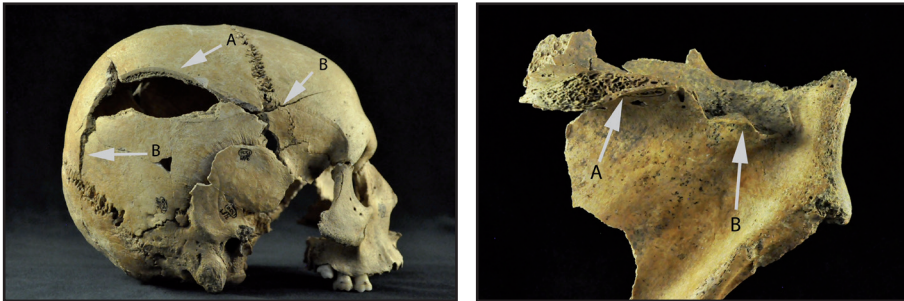


Fig. 4a-4b. Skeleton 107 from Gloucester showing sharp force trauma following the reconstruction (from Valoriani *et al.*, 2017).

Skeletal reconstruction is not only beneficial for research, forensic investigations and teaching purposes but also museum display. Many museums exhibit skeletal specimens recovered from different sites in Great Britain. The display of human remains can be a controversial topic if these are less than 100 years old. In archaeological remains, these can be displayed if they do not outrage public decency (Woodhead, 2013). Museums are accessed by both experts and the general public, often unfamiliar with physical anthropology. A fragmented skull would not be understood in its completeness by someone unfamiliar with human anatomy. If a fragmented skeleton with trauma or pathology were displayed, it would not be possible to appreciate and observe the condition, as the nature of the remains would not allow a comprehensive vision. If the skeleton instead underwent a complete restoration, the public and researchers would benefit from better observing the case. A further advantage of cranial reconstruction consists in offering the opportunity of carrying out radiographic analysis and facial reconstruction. Many techniques are used for facial reconstruction, and the digital option is prevalent (Wilkinson, 2004). For the digital reconstruction, the skull needs to be laser scanned so that the anthropologist can work on the digital copy. A fragmented skull can be reconstructed virtually, but every cranial fragment needs to be scanned. This method is time-consuming, and the equipment's cost could limit the researchers, Universities and Museums involved. Furthermore, as Komar *et al.* (2012) stated, the resolution of the images for some more complex geometries, such as the skull, can be inaccurate.

Cranial reconstruction is ideal, as a complete reconstruction takes around three hours for experts trained for the task (Valoriani, 2019). This would also

be suitable for a later scanning of the skull, which would be a faster approach than a digital reconstruction. This technique is frequent in museums, and it increases the chance of engaging the visitors. Simultaneously, facial reconstruction is also used to aid in forensic cases, where the recovery of fragmented remains is not an unusual event. Reconstruction of burnt remains is proposed by Grevin *et al.* (1998), as accidents such as burning planes, cars, houses, and public places or forests can lead to the bones' high fragmentation. These scenarios can hinder the traits used by the anthropologist to estimate the biological profile of the victim. In this case, the authors report an example from a forensic context that leads to the victim's identification thanks to the reconstruction of the mandible, confirming the importance of this approach.

In conclusion, the method proposed by the authors is not difficult to be performed by trained anthropologists, as well as the preparation of the wax applied is a straightforward process, not particularly time-consuming, neither expensive. Therefore, the authors hope that the present paper could represent a step forward to preserve better and study human skeletal remains, as a biological profile cannot be considered complete with the lack of information caused by the fragmentary nature of the remains.

ACKNOWLEDGEMENT — The authors are extremely grateful to Vitaliano Rossi, former technician at the University of Florence, Department of Evolutionary Biology «Leo Pardi», for his contribution in the development of the methodology presented in the present article. A special thank goes to Liverpool John Moores University for funding the research through the award of a PhD fellowship. The authors also thank the Poulton Research Project and Gloucester City Museum for the loan of the skeletal collections from Poulton and Southgate Street, housed at Liverpool John Moores University.

BIBLIOGRAPHICAL REFERENCES

- Acsádi, G., Nemeskéri, J., Balás, K. 1970. *History of human life span and mortality*. Akadémiai kiado: 215-234.
- Blau, S. 2017. How traumatic: a review of the role of the forensic anthropologist in the examination and interpretation of skeletal trauma, *Australian journal of forensic sciences*, 49(3): 261-280.
- Borrini, M. 2007. *Archeologia forense: metodo e tecniche per il recupero dei resti umani: compendio per l'investigazione scientifica*. Lo scarabeo.
- Borrini, M., Giachetti, C. 2012. A Forensic Anthropological Analysis of the Seventh-Century Lombard Warrior's Remains, *Journal of Biological Research*, LXXXIV: 222-223.
- Borrini, M., Mariani, P.P., Murgia, C., Rodriguez, C., Tumbarello, M.V. 2012a. Contextual taphonomy: superficial bone alterations as contextual indicators, *Journal of Biological Research-Bollettino della Società Italiana di Biologia Sperimentale*, 85(1): 217-219.

- Borrini, M., Mariani, P.P., Murgia, C., Rodriguez, C., Tumbarello, M.V. 2012b. Contextual Taphonomy: Superficial Bone Alterations as Contextual Indicators. In: Atti del XIX Congresso Associazione Antropologica Italiana, *Journal of Biological Research*, 84(1): 217-219.
- Borrini, M., Solaini, P., Golloher, M.J.D. 2012c. Preliminary Analysis of the Pathological and Traumatic Conditions on Skeletal Samples from a Plague Cemetery of Venice, *Journal of Biological Research*, 85(1): 220.
- Borrini, M., Riccadonna, L., Borrini, C. 2014a. A possible juvenile hypochondroplasia case from the mass grave of Lazzaretto Nuovo Island (Venice), *Museologia Scientifica e Naturalistica*, 10(2): 97-101.
- Borrini, M., Donati, M., Murgia, C. 2014b. Skeletal remains from the cemetery of Lazzaretto Nuovo (Venice): a preliminary analysis, *Museologia Scientifica e Naturalistica*, 10(2): 85-90.
- Bowron, E.L. 2003. A new approach to the storage of human skeletal remains, *The conservator*, 27(1): 95-106.
- British Association of Biological Anthropology and Osteoarchaeology. 2018. Code of Practice of the British Association of Biological Anthropology and Osteoarchaeology [online]. Internet Edition: <http://www.babao.org.uk/assets/Uploads-to-Web/code-of-practice.pdf>. (Accessed 27th April 2018).
- Brothwell, D.R. 1981. *Digging up bones: the excavation, treatment, and study of human skeletal remains*. Cornell University Press.
- Buikstra, J.E. 1994. *Standards for data collection from human skeletal remains*. Arkansas archaeological survey research series, 44.
- Carew, R.M., Morgan, R.M., Rando, C. 2019. A preliminary investigation into the accuracy of 3D modeling and 3D printing in forensic anthropology evidence reconstruction, *Journal of forensic sciences*, 64(2): 342-352.
- Christensen, A.M., Sylvester, A.D. 2008. Physical matches of bone, shell and tooth fragments: a validation study, *Journal of Forensic Sciences*, 53(3): 694-698.
- Collings, A.J., Brown, K. 2020. Reconstruction and physical fit analysis of fragmented skeletal remains using 3D imaging and printing, *Forensic Science International: Reports*, 2: 1-6.
- Cronyn, J.M. 1990. *The Elements of Archaeological Conservation*. Routledge.
- Erickson, D., Grueso, I., Griffith, S.J., Setchell, J.M., Thompson, T.J.U., Thompson, C.E.L., Gowland, R.L. 2017. Towards a Best Practice for the Use of Active Non-contact Surface Scanning to Record Human Skeletal Remains from Archaeological Contexts, *International journal of osteoarchaeology*, 27(4): 650-661.
- Gabherr, S., Baumann, P., Minoiu, C., Fahrni, S., Mangin, P. 2016. Post-mortem imaging in forensic investigations: current utility, limitations, and ongoing developments, *Research and Reports in Forensic Medical Science*, 6: 25-37.
- Grévin, G., Bailet, P., Quatrehomme, G., Ollier, A. 1998. Anatomical reconstruction of fragments of burned human bones: a necessary means for forensic identification, *Forensic science international*, 96(2-3): 129-134.
- Huotilainen, E., Jaanimets, R., Valášek, J., Marcián, P., Salmi, M., Tuomi, J., Wolff, J. 2014. Inaccuracies in additive manufactured medical skull models caused by the DICOM to STL conversion process, *Journal of cranio-maxillofacial surgery*, 42(5): e259-e265.
- Komar, D.A., Davy-Jow, S., Decker, S.J. 2012. The use of a 3-D laser scanner to document ephemeral evidence at crime scenes and postmortem examinations, *Journal of forensic sciences*, 57(1): 188-191.

- Lauria, G., Sineo, L., Ficarra, S. 2022. A detailed method for creating digital 3D models of human crania: an example of close-range photogrammetry based on the use of Structure-from-Motion (SfM) in virtual anthropology, *Archaeological and Anthropological Sciences*, 14(3): 1-13.
- Mays, S., Brickley, M., Dodwell, N. 2004. *Human Bones from Archaeological Sites: guidelines for producing assessment documents and analytical reports*. English Heritage.
- Odegaard, N., Cassman, V. 2006. Treatment and invasive actions. In: V. Cassman, N. Odegaard, J. Powell (eds), *Human Remains: Guide for Museums and Academic Institutions*. Altamira Press Lanham, MD: 77-95.
- Ortner, D.J. 2003. *Identification of pathological conditions in human skeletal remains*. Academic press.
- Pokines, J.T., Baker, J.E. 2014a. Effects of burial environment on osseous remains, *Manual of forensic taphonomy*: 73-114.
- Pokines, J.T., Baker, J.E. 2014b. Effects of recovery methods. *Manual of forensic taphonomy*: 447-465.
- Silva, D.N., De Oliveira, M.G., Meurer, E., Meurer, M.I., Da Silva, J.V.L., Santa-Bárbara, A. 2008. Dimensional error in selective laser sintering and 3D-printing of models for craniomaxillary anatomy reconstruction, *Journal of cranio-maxillofacial surgery*, 36(8): 443-449.
- Valoriani, S. 2019. *Cranial remains from the graveyard to the laboratory: restoration, conservation and craniometric analysis of medieval British skeletal samples*. Doctoral dissertation, Liverpool John Moores University.
- Valoriani, S., Eliopoulos, C., Borrini, M. 2017. Sharp force trauma death in a young individual from medieval Gloucester, *The American journal of forensic medicine and pathology*, 38(2): 111-114.
- Wilkinson, C. 2004. *Forensic facial reconstruction*. Cambridge University Press.
- Woodhead, C. 2013. Care, custody and display of human remains: legal and ethical obligations. In: M. Giesen (ed.), *Curating human remains: caring for the dead in the United Kingdom*. The 'Heritage matters' series, 11. Woodbridge: Boydell: 1-42.