

Review

Pilonidal cysts: what's new? Technological innovations and the importance of Wound Management

Citation: Colella R., De Mola A., Azzarone F. "Pilonidal cysts: what's new? Technological innovations and the importance of Wound Management" (2023) *infermieristica journal* 2(1): 29-38. DOI: 10.36253/if-1898

Received: November 14, 2022

Revised: December 2, 2022

Just accepted online: April 5, 2023

Published: April 30, 2023

Copyright: © 2023 Colella R., De Mola A., Azzarone F. This is an open access, peer-reviewed article published by *infermieristica Editore & Firenze University Press* (<http://www.fupress.com/>) and distributed under the terms of the Creative Commons Attribution License, which permits unrestricted use, distribution, and reproduction in any medium, provided the original author and source are credited.

Data Availability Statement: All relevant data are within the paper and its Supporting Information files.

Competing Interests: The Author(s) declare(s) no conflict of interest.

Rosa Colella¹, Angela De Mola², Filippo Azzarone³

¹ RN, IRCCS Policlinico San Matteo Foundation, Pavia, Italy

² RN, ASST Ospedale Maggiore di Crema, U.O. Internal Medicine, Italy

³ RN, U.O.C. of Resuscitation 1, University Hospital of Bari, Italy

Abstract: Pilonidal cysts typically manifest with the formation of ulcers or orifices, predominantly in the sacrococcygeal region. It generally affects young males between 15 and 30 years of age. It has a reported incidence rate of 26 per 10,000 people and affects men 2.2 times more than women. It often tends towards a chronic course if the correct diagnostic-therapeutic course is not taken. Surgical treatment of pilonidal cysts is only recommended in the presence of symptomatic disease and is the only effective treatment in this case.

Improper cleaning of the wound bed slows healing and may promote complications such as infection or biofilm formation, leading to recurrence. In addition to surgical or conservative treatment, an adequate assessment of the skin tissue is required by a specialist wound care professional who can recognise all local signs that impede healing.

Hence, the role of a specialist in Vulnology in the multidisciplinary team and the post-operative phase may be necessary to take care of the person in a dedicated outpatient clinic to assess the patient and adopt tailored local treatment strategies. The article proposes a narrative review of the latest available evidence, considering the last ten years, regarding the surgical approaches and new biotechnologies for wound management, with special attention to new treatment modalities and critical issues that are still to be investigated.

Keywords: Sinus, Pilonidal Cyst, Wound Care, Infected Wound, Nurse Specialist, Biofilm

Introduction

Pilonidal sinus disease (PSD) is a chronic and painful soft tissue disease mainly affecting young people. It is a socially disabling problem that causes physical and psychological suffering, significant financial burden to the patient, family, and community, as well as the health care system,

given the high overall costs implied.

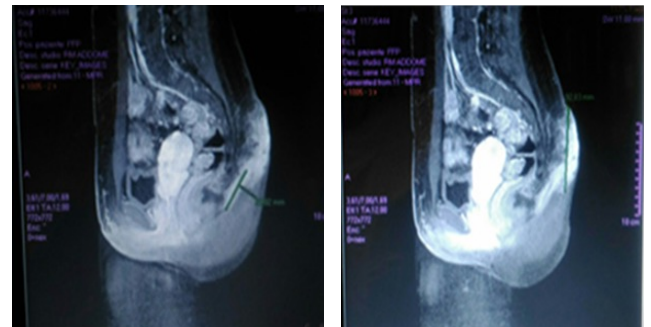
The expression Pilonidal Cyst is derived from the Latin "pilus," meaning "hair", and nidus, meaning 'nest.' The "pilonidal disease" (PSD), whose name was given by Richard Hodges in 1880 and first described in 1833 by Herbert Mayo, generally affects young males aged between 15 and 30 years¹.

Pilonidal sinus disease (PSD) usually consists of fistulas and cysts, more frequently located in the sacrococcygeal area and intergluteal groove between the skin and the subcutaneous fatty tissue, and the lesion only rarely reaches the muscular layer. The most common signs and symptoms of PSD include a swelling area, which is frequently painful and erythematous, and secretions that may be serous, hematic, purulent, maleodorant, and often associated with fever and malaise. In sporadic and severe cases PSD also causes fistulas⁵.

The etiopathogenesis of pilonidal cysts remains uncertain. The hairs initially burrow into the dermis, creating an inflammatory reaction that spreads to the subcutaneous cellular tissue. Subsequently, a cavity is formed, creating primary and secondary orifices. During puberty, sex hormones stimulate the hair follicles and pilosebaceous glands, and, as a result, the hair follicle is stretched by keratin. Initially, the keratin obstructs the enlarged follicle; then, the follicle becomes inflamed and bursts, forming, in the end, a pilonidal microabscess. Certain positions, such as prolonged sitting, are more likely to favour this skin condition; moreover, the lesion is favoured by specific working or sports activities that expose the sacrococcygeal region to microtraumas². In rare cases, PSD affects other body regions such as the penis, clitoris, scrotum, anus, scalp, chin, nose, face, neck, navel, groin, pubis, abdominal wall, axilla, sternum, breast, intermammary area and interdigital spaces. John Bascom's studies have shown how PSD is an acquired condition, albeit with a proportion of favourable genetic factors such as familiarity. PSD risk factors include male sex, family history, obesity, trauma or irritation, sedentary lifestyle, hirsutism, coccyx conformation and poor hygiene¹.

The diagnosis of PSD is based on objective examination; however, imaging may be supportive in targeting selected multi-recurrent and complex cases or excluding other diseases. Imaging includes ultrasound with a linear probe of skin and subcutis and nuclear magnetic resonance imaging (MRI) Fig 1. An anoscopy or proctoscopy may be helpful. Suppose one of the fistulous orifices is very close to the anus. In that case, performing an anorectal ultrasound with a 360° rotating probe is helpful to exclude a perianal fistula (differential diagnosis and exclusion of dual coexisting pathology).⁵

Fig. 1a/1b MRI of the sacrococcygeal region in patients with MP (Images courtesy of patient).



Pilonidal cysts and differential diagnosis.

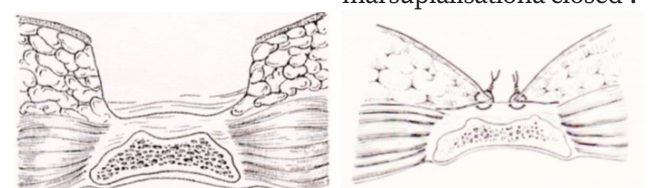
Due to the clinical manifestation of pilonidal cysts, differential diagnosis with other dermatological pathologies should be considered, including hidradenitis suppurativa, pyoderma gangrenosum, perianal fistula, perirectal abscess, sacral osteomyelitis, furuncle, infected sebaceous cyst, actinomycosis, sacrococcygeal teratoma, sacrococcygeal chordoma or other presacral tumour, dorsal dermal sinus, Crohn's disease, luetic granuloma, tubercular granuloma, and desmoplastic neurotropic melanoma. Malignant degeneration of pilonidal cysts is a rare occurrence since, from the early 1990s, very few cases have been observed.⁶

Surgical treatment

Surgical treatment of pilonidal cysts is recommended only in symptomatic disease, representing the only effective treatment. The most traditional surgical procedure is **Marsupialisation** (Fig. 2), which consists of the en bloc removal of the granuloma, including its fistulous tracts and overlying skin. The open technique of marsupialisation involves the healing process of the residual cavity by second intention; in contrast, the closed technique involves direct saturation of the wound or by using sliding flaps.

Fig. 2a Open technique⁷.

Fig.2b Technical marsupialisation closed⁷.



Other surgical techniques used over the years are described as follows:

Sinusectomy

It is a mini-invasive technique consisting of removing the dimples and midline sinus under local anaesthesia using a scalpel or scissors; this process leads to complete subcutaneous excision of the sinus tract.

Bascom Technique I (Pit Picking)

This technique, which was first devised in 1980, involves the removal of small hair entry holes and a lateral incision equal to the size of the fistula. The recurrence rate after pit picking is expected to be 8 to 26% in a period ranging from 12 and 120 months after surgery.⁶⁻⁷

Bascom II technique (Cleft Lift)

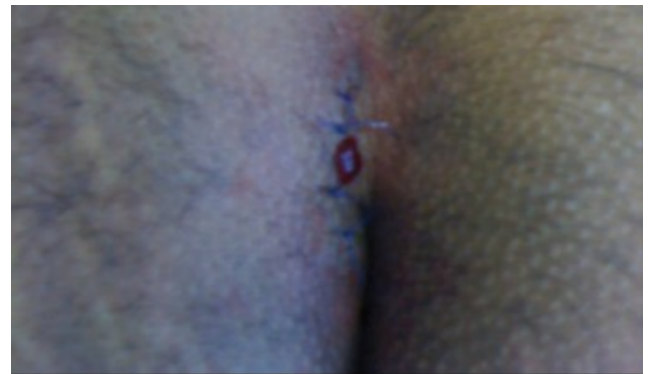This technique, which was first devised in 1987, consists of removing breast tracts and creating a full-thickness stable skin flap across the cleft and closed off the midline. Adipose tissue is used to fill the previous space of the gluteal cleft. Wound dehiscence, mainly caused by infection of the subcutaneous seroma, is a recurrent event (15-40%).⁸

Gips' technique

More recently, Gips et al., have modified Bascom's technique, using a trephine of various diameters to excise the fossae and debride underlying cavities and tracts, thus removing only the cyst and fistulous tracts⁹. Biopsy punches (i.e., instruments with sharp blades to create a wound with well-defined edges that can be easily treated), can also be used to excise pits.³

Off-midline treatment indicates that the suturing technique does not occur on the midline but laterally (fig.4); notably, off-midline procedures are statistically superior to midline closure in terms of healing, as evidenced by a Cochrane review . Currently, many experts consider the off-midline approach a gold standard for pilonidal sinus management.⁹

Fig.4 Image of suture outside the midline after excision¹².



The future of Pilonidal Sinus Surgery: a shift to endoscopic treatments

The significant morbidity and recurrence of PSD have led to the development of less invasive endoscopic methods, such as the Video Assisted Anal Fistula Treatment (VAAFT), the Video Assisted Ablation of the Pilonidal Sinus (VAAPS) and the Endoscopic Pilonidal Sinus Treatment (EPiST). All these treatments, performed under local anaesthesia, are video-assisted using a fistuloscope. The procedures have in common a diagnostic phase of tissue exploration to identify incar hairs, infection, or abnormal tissue, followed by an antiseptics and healing phase in which wound cleaning, cautery of the fistula and subsequent closure are performed¹⁰⁻¹¹. In 2020, a new method called EPSI-R (endoscopic pilonidal sinus resection) using a resectoscope was first described in the journal Techniques in Coloproctology. After introducing the endoscope and exploring the affected area, a resection of the injured area is performed, followed by irrigation with saline solution to remove cellular debris. After the cleaning phase, the authors described the use of phenol to promote healing. The procedure is performed during epidural anaesthesia¹² (Fig.5-6).

Fig. 5-6. EPSIT technique, images through fistuloscope.¹³

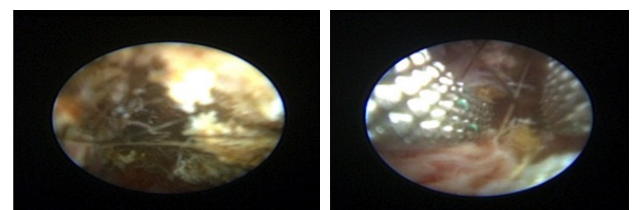


Table.1 Surgical treatment types of pilonidal cysts. Source: <https://www.siccr.it> (Italian Society of Colon-Rectal Surgery)⁷

Surgical treatments (SICCR,2019)⁷	
<p>Plastic Surgery:</p> <ul style="list-style-type: none"> • Z' plastic • Cleft Lift or 'Bascom 2' • Rhomboid flap • Karydakias flap • Limberg flap • Lembo Gluteus Maximus • Bilateral Gluteal Advancement Flap • V-Y Gluteus flap • Upper Gluteal Perforating Artery flap • Triangular Crossed Flaps • Modified Dufourmental flap with superior peduncle. 	<p>Minimally invasive techniques:</p> <ul style="list-style-type: none"> • Lord-Millar intervention (1965, involves the use of small pipe cleaners) • Bascom surgery (1980, small lateral incision and medial 'grain of rice' incisions by means of a small-blade scalpel) • Sinotomy operation (2005, Al-Naami) • Gips surgery (2008, slight modification of Bascom, involves the use of biopsy 'punches' instead of the small-bladed scalpel) • Sinusectomy surgery (2011, Soll) • LIFT Technique (Ligation of Intersphincteric Fistula Tract) • Intervention of E.P.Si.T. (2014, Meinero) • Anal Fistula Plug (Armstrong, 2006) • Technique (EPSI-R) (Yuksel, 2020) • VAAPS and VAAFT technology • FILAC technique, laser fistula closure • Carotid surgery with cystectomy and fistulectomy (combines the principles and technique of Bascom's intervention with those of Gips)

Conservative treatments

Phenol injections

These are used for the treatment of mild to moderate pilonidal cysts. After using a curettage, phenol is administered through the existing orifices or dimples and left in place for 1 to 3 minutes, followed by saline washing ¹¹.

Laser therapy

It is a new minimally invasive treatment. The presence and consistency of hairs can lead to an inflammatory response with sinus formation, so using a laser can help prevent future disease or recurrence ¹¹.

Platelet gels

Some authors have described platelet-rich plasma or autologous adipose tissue as effective in reducing postoperative pain and accelerating wound healing¹³. A randomised controlled trial that examined the use of platelet gel compared with standard post-operative flat dressing found that the average healing time of the wound was 8.7 ± 1.18 weeks for the control arm and 4.8 ± 0.87 for the treatment arm (p < 0.01) ¹.

Fibrin glue

Fibrin glue comprises a mixture of fibrinogen, thrombin, factor XIII, calcium and aprotinin. It is used in combination after curettage treatments of the fistulous tracts or after minimal excision of the midline dimples¹⁴. Studies reporting this approach are lacking; however, in a prospective study by Sian et al., a sample of 146 patients underwent simple scraping of the sinus tracts followed by fibrin glue application; the authors described that a curettage rate of 96% of the examined sample was obtained after at least two fibrin treatments; nevertheless, the evidence regarding this approach remains scarce¹⁵.

Negative pressure therapy (NPTW)

NPTW used to treat chronic wounds facilitates granulation and healing process and can also reduce septic wound complications due to the continuous suction that keeps a clean wound bed and removes debris and bacteria (Figure 7). The quality of scientific evidence is low; however, in a 2012 randomised controlled trial, the NPTW approach appeared to reduce wound healing time, recovery and pain after surgery¹⁶.

Other treatments

Medical honey

Medical honey exerts antibacterial action using a natural cleansing of the wound bed and oxidative activity. Saleh et al., (2022) evaluated the application of medical honey after pilonidal cyst resection for PSD with secondary intention healing; they found a shorter healing time in the intervention group, and the patients had a faster return to daily activities.¹⁷

Silver nitrate

Silver nitrate is a lytic agent widely used among wound care products and dressings to manage complex wounds. In several clinical conditions, such as perianal fistula, silver nitrate has been shown to accelerate wound healing by removing the excessive granulation tissue responsible for epithelial cell destruction and fibroblast activation. A retrospective study by Kanat et al., (2020) evaluated the cure rate and adverse effects of silver nitrate application in 56 patients affected by PSD and confirmed a generally high healing rate and low complications and recurrences in these patients.¹⁹

Collagen

Collagen is a structural protein that gives the skin its tensile strength and draws fibroblasts and keratinocytes to the wound to promote angiogenesis and re-epithelisation. Collagen dressings stimulate new tissue growth and promote the deposition and organisation of new collagen fibres and granulation tissue in the wound bed. These dressings chemically bind to matrix metalloproteinases (MMPs) in the extracellular fluid of wounds. Collagen can therefore be a valuable contributor to helping rebuild new tissue. However, the wound bed must be clean and cleansed to favour its full function.²⁰

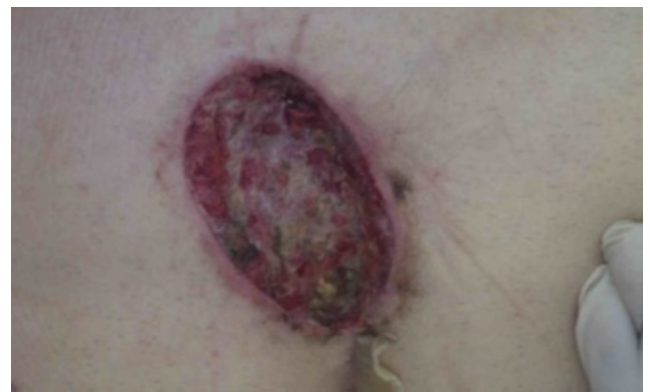Dressings with oil-reactive oxygen species (ROS) releasing matrix

Among the therapeutic innovations, these types of dressings are rapidly emerging. The oil-based medical device is enriched with oxygen, ensures the continuous release of ROS, and makes oxygen available in the wound site. This process contributes to maintaining suitable physical-chemical conditions (e.g., a low PH), and the interaction with the fluids present at the site indirectly supports and enhances the antibacterial and antifungal function, which is already typical of the inflammatory phase. As highlighted by clinical data, the release of ROS favours the establishment of

a local microenvironment which in turn facilitates the subsequent release of the same ROS by the cells of the loco-regional immune system (typical of the inflammatory phase). This mechanism enables the establishment of a natural metabolic process. In addition, the oleic matrix allows for an optimal moist microenvironment, avoiding maceration of the wound bed and performing a protective film-forming action, which favours fibroblast proliferation and re-epithelialisation.²¹

Other treatments include autologous fibroblast or mesenchymal cell grafting and gelatinous thrombin matrix.⁹

Fig.7. Wound two days after excision of pilonidal cyst treated with NPTW.²³



The importance of Wound bed preparation and wound management: the point of view of the nurse specialist in Wound Care.

The nurse Wound Care specialist has a fundamental role in care planning and local management of skin ulcers; depending on the approach or surgical technique one decides to undertake, pilonidal cysts can heal by first intention or secondary intention. The role of the Vulnology specialist can be crucial when surgery fails due to recurrences or infections; this figure is also essential to promote secondary intention healing through the use of advanced dressings and conservative treatments. The Vulnology specialist has acquired principles of tissue repair based on the TIMERS framework (fig. 8); this is a clinical reference tool for experts, which is considered the basic strategy in modern wound management because its adherence favours all tissue conditions leading to physiological repair²². Through this knowledge, the experienced practitioner acts according to best-practice; for example, they are capable of observing the tissue and detecting visual signs of chronicity, or complications, such as the presence of a suspected biofilm, which, if

untreated, represents one of the risk factors for non-healing; they are also prepared to choose the appropriate dressings and biotechnological innovations, tailored to the wound condition.

Cleaning the wound of bacteria that can appear dangerous and restoring the appropriate local conditions such as acidic PH and moist microenvironment are ideal conditions to promote physiological healing; these principles are systematically promoted through two approaches described here, Wound bed Preparation and Wound Hygiene, which, in addition to TIMERS, represent the most current wound management logics for the management of skin lesions (including those of surgical origin) that tend to become chronic.

Wound bed preparation

Wounds heal faster if they are clean and free of necrotic tissue, bacteria or other debris.

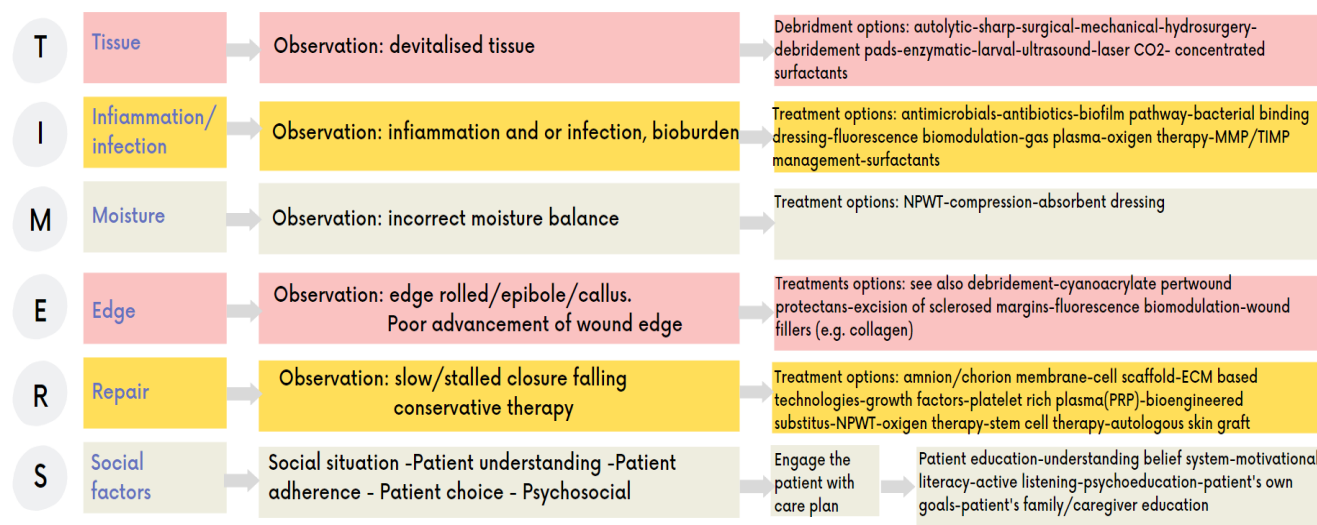
The cleansing process, or the action of washing and cleaning the wound/ulcer, is an essential step in wound management. The act of washing involves the removal of tissue debris, surface germs, any dressing residues and other poorly adhered but macroscopically visible surface materials that may impede and retard the proliferative process. According to good clinical practice, cleansing should be performed at each dressing change, using appropriate methods and materials, such as irrigation and rinsing, and removing dissolved material with gauze.²³

In addition to sterile solutions such as the 0.9% saline, the literature supports using cooled, boiled or bottled water and ringer lactate. Recent evidence suggests that detergent solutions with surfactant action could also be used in addition to simple detergents (water and solutions mentioned above) at low concentrations or contain Polyhexamethylene Biguanide (PHMB), which in some cases directly facilitates biofilm breakdown.

Wound bed cleansing and decontamination strategies are part of the practices defined in the literature as Wound Hygiene (Fig. 9)²⁴. A correct assessment involves an evaluation of the wound and the patient and possibly referring them to a specialised clinic. Knowing how to observe the tissue and its clinical presentation, in addition to history evaluation, can make a difference in the resolution of the clinical case. The observation performed during standard routine dressing manoeuvres can help suspect the presence of biofilm or infection.¹⁶

A correct assesment therefore involves assessing the wound and the patient, and if possible taking them to a dedicated clinic. Knowing how to observe the tissue and its clinical presentation in addition to evaluating the history can make a difference in the resolution of the clinical case. The findings that are made during normal dressing manoeuvres can be useful in suspecting the presence of biofilm or infection 16.

Fig.8 TIMERS framework for the management of difficult-to-heal wounds (Aktin, et al, 2019, mod.)²⁵

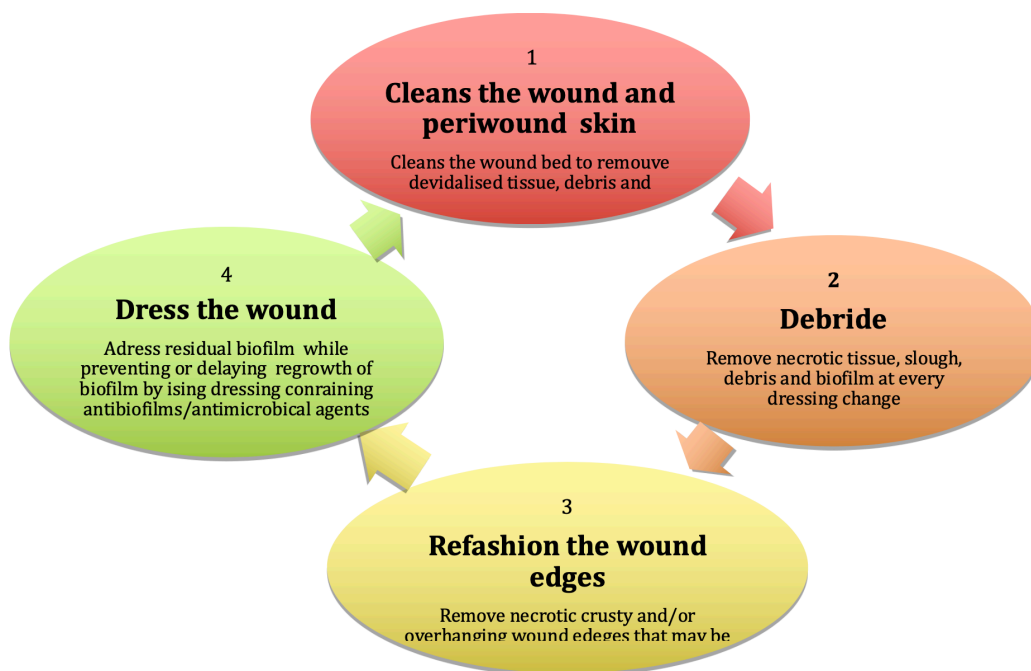


Biofilm management

The biofilm is a community of microorganisms that adhere to each other on the surface of the ulcer; such bacteria are embedded in a matrix of polymers and sugars (EPS) and constitute a real

'barrier' against dressings and treatments, therefore hindering the healing process. Recent studies have shown that about 80% of chronic ulcers exhibit a biofilm, thus representing a significant problem to be considered.

Fig.9 The four steps of Wound Hygiene (Murphy C, et al, 2020, mod)² .



The presence of a biofilm is established by specific examinations such as skin biopsy, but the clinician may observe suspicious signs of biofilm that are as follows:²⁵

- fragile bleeding tissue;
- medium or abundant dark red exudate (called haemorrhagic), indicating high bacterial and debris load;
- antibiotic therapy failure (biofilm has a barrier effect that does not allow penetration of antibiotics and non-targeted products);
- negative culture swab despite the presence of signs of infection;
- translucent background.

Biofilm formation involves 3 phases: the first phase is characterised by the attachment of bacteria to a surface; the second is the constitution and maturation of a colony, and finally, the detachment of the bacteria that may colonise new areas. Cleansing can dilute the bacterial load during the first phase; in contrast, mechanical debridement or surgery is required to promote biofilm breakdown in combination with targeted antibacterial products (Ag⁺, honey dressings, ROS-releasing, Iodine-containing) to prevent biofilm reformation.

Treatment of infection

Infection is a factor that promotes chronicity; as reported by international documents, antimicrobial agents for topical use are conditioned by the type of wound, also in relation to developed bacterial resistance. In Italy, antiseptics derived from chlorine are widely used (0.05% electrolytic chloride), also sustained by the evidence of histolesivity absence (i.e., they do not cause osmotic imbalance). The signs of infection are²⁶:

- reddened and hot perilesional skin (cellulite);
- malodour;
- abundant purulent exudate: if *Pseudomonas Auriginosa* or *Escherichia Coli* colonise the lesion, the exudate may also appear greenish or brown, respectively. It can also appear haemorrhagic, which is an indication of a high bacterial load;
- perilesional swelling/oedema.

Clinical case:

A 23-year-old girl with a silent medical history and the onset of pilonidal cysts at 18 underwent seven surgical operations in five years: five sinusotomy operations, one using the Bascom technique⁶ and one using the Gips technique³. After each

operation and removal of the stitches, the lesions never healed entirely; instead, they showed signs of recurrence and infection from the beginning.

In November 2019, a Vulnology nurse specialist observed the lesion and suspected the presence of biofilm; the lesion was fragile and easily bleeding, with medium to abundant dark red (haemorrhagic) exudate. Cleansing of the lesion bed with an antiseptic cleanser containing PHMB (according to WBP principles) was initiated. A new-generation medical device was then applied; it consisted of a gel made of an oleic matrix that released reactive oxygen species (ROS). This approach allowed the creation of a suitable local microenvironment that favoured bacterial decontamination and guaranteed a humid microenvironment, thus restoring the conditions that led to a physiological restoration of proliferative processes. The management time for this lesion was approximately 2.5 months. After six years, the patient was able to benefit from total healing, resuming sports activities that had been suspended until then, and improving her quality of life. This clinical case highlights how the role of the clinical specialist can make a difference and provide appropriate and targeted support to resolve complex clinical cases.

Conclusions

Currently, PSD remains a significant problem in general surgery. Many surgical techniques indicate that a single approach towards therapeutic success is unlikely, which is also associated with frequent complications that lead to patient dissatisfaction and healthcare provider frustration. Moreover, what should be considered are the social and psychological aspects entailed, for which it would be helpful to provide support if necessary. Intuitively, PSD can harm the patient's quality of life, especially if the wound shows signs of chronic evolution. The Wound Care nurse specialists could play the role of case managers since they could plan personalised diagnostic-therapeutic paths and offer support to family members and other healthcare providers involved at the patient's home. Thus, the involvement of the specialist nurse in the team potentially guarantees uniform care planning and contributes to the dissemination of evidence-based procedures. Moreover, the possibility of a dedicated outpatient clinic for the care of hard-to-heal wounds may result in better continuity of care and improved healing process while at the same time reducing the need for readmission of the person in the clinical setting. Good documentation is also essential for ensuring the continuity of

surgical wound care. Another additional value may be in promoting early recognition and interventions for surgical site infections.

© The Author(s), under exclusive licence to infermieristica Editore Limited 2023.

References

1. Gips M, Melki Y, Salem L, Weil R, Sulkes J. Minimal surgery for pilonidal disease using trephines: description of a new technique and long-term outcomes in 1,358 patients. *Dis Colon Rectum*. 2008;51(11):1656-1663. doi:10.1007/s10350-008-9329-x.
2. Doll D, Bosche FD, Stauffer VK, et al. Strength of Occipital Hair as an Explanation for Pilonidal Sinus Disease Caused by Intruding Hair. *Dis Colon Rectum*. 2017;60(9):979-986. doi:10.1097/DCR.0000000000000795
3. Bosche F, Luedi MM, van der Zypen D, Moersdorf P, Krapohl B, Doll D. The Hair in the Sinus: Sharp-Ended Rootless Head Hair Fragments can be Found in Large Amounts in Pilonidal Sinus Nests. *World J Surg*. 2018;42(2):567-573. doi:10.1007/s00268-017-4093-5
4. Bascom J. Pilonidal disease: origin from follicles of hairs and results of follicle removal as treatment. *Surgery*. 1980;87(5):567-572.
5. Website: www.siccr.org. (Italian association of colorectal surgery's web site) viewed on 10/11/2022.
6. Vertaldi S, Anoldo P, Cantore G, et al. Histopathological Examination and Endoscopic Sinusectomy: Is It Possible?. *Front Surg*. 2022;9:793858. Published 2022 Mar 3. doi:10.3389/fsurg.2022.793858.
7. Segre D, Pozzo M, Perinotti R, Roche B; Italian Society of Colorectal Surgery. The treatment of pilonidal disease: guidelines of the Italian Society of Colorectal Surgery (SICCR). *Tech Coloproctol*. 2015;19(10):607-613. doi:10.1007/s10151-015-1369-3
8. Al-Khamis A, McCallum I, King PM, et al. Healing by primary versus secondary intention after surgical treatment for pilonidal sinus. *Cochrane Database Syst Rev*. 2010;1:CD006213.
9. Kober MM, Alapati U, Khachemoune A. Treatment options for pilonidal sinus. *Cutis*. 2018;102(4):E23-E29.
10. Milone M, Velotti N, Manigrasso M, Milone F, Sosa Fernandez LM, De Palma GD. Video-assisted ablation of pilonidal sinus (VAAPS) versus sinusectomy for treatment of chronic pilonidal sinus disease: a comparative study. *Updates Surg*. 2019;71(1):179-183. doi:10.1007/s13304-018-00611-2.
11. Meinero P, Mori L, Gasloli G. Endoscopic pilonidal sinus treatment (E.P.Si.T.). *Tech Coloproctol*. 2014;18(4):389-392. doi:10.1007/s10151-013-1016-9.
12. Yuksel BC, Aslan Y, Er S. Endoscopic pilonidal sinus resection (EPSI-R): a new method. *Tech Coloproctol*. 2020;24(10):1091-1092. doi:10.1007/s10151-020-02243-4.
13. Lesalnieks I, Ommer A, Herold A, et al. German National Guideline on the management of pilonidal disease: update 2020. *Langenbecks Arch Surg* (2021).
14. Win M, Went TR, Ruo SW, et al. A Systematic Review of Fibrin Glue as an Ideal Treatment for the Pilonidal Disease. *Cureus*. 2021;13(8):e16831. Published 2021 Aug 2. doi:10.7759/cureus.16831.
15. Sian TS, Herrod PJJ, Blackwell JEM, Hardy EJO, Lund JN. Fibrin glue is a quick and effective treatment for primary and recurrent pilonidal sinus disease. *Tech Coloproctol*. 2018;22(10):779-784. doi:10.1007/s10151-018-1864-4.
16. Banasiewicz T, Bobkiewicz A, Borejsza-Wysocki M, et al. Portable VAC therapy improve the results of the treatment of the pilonidal sinus--randomized prospective study. *Pol Przegl Chir*. 2013;85(7):371-376. doi:10.2478/pjs-2013-0056.
17. Salehi V, Yavari Barhaghtalab MJ, Mehrabi S, et al. Does application of honey improve surgical outcome in pilonidal cyst excision with secondary intention healing? A prospective randomized placebo-controlled clinical trial. *Perioper Med (Lond)*. 2022;11(1):1. Published 2022 Jan 10. doi:10.1186/s13741-021-00237-w.
18. Attaallah W, Tuney D, Gulluoglu BM, Ugurlu MU, Gunal O, Yegen C. Should we consider topical silver nitrate irrigation as a definitive nonsurgical treatment for perianal fistula?. *Dis Colon Rectum*. 2014;57(7):882-887. doi:10.1097/DCR.0000000000000143.
19. Kanat BH, Yazar FM, Kutluer N, et al. Use of Silver Nitrate Application as Mini-Invasive Treatment of Pilonidal Sinus Disease. *Chirurgia (Bucur)*. 2020;115(6):775-782. doi:10.21614/chirurgia.115.6.775.
20. Mathew-Steiner SS, Roy S, Sen CK. Collagen in Wound Healing. *Bioengineering (Basel)*. 2021;8(5):63. Published 2021 May 11. doi:10.3390/bioengineering8050063.
21. Cassino R, Ippolito AM, Cuffaro P, Corsi A, Forma O. Evaluation of the effectiveness of a hyperoxidized oil-based medication in the treatment of skin lesions: observational study. *Minerva Chir*. 2015;70(1):23-31.
22. Atkin L, Bućko Z, Conde Montero E, et al. Implementing TIMERS: the race against hard-to-heal wounds. *J Wound Care*. 2019;23(Sup3a):S1-S50. doi:10.12968/jowc.2019.28.Sup3a.S1.
23. Bellingeri A. *Handbook of wound care: for the prevention and treatment of skin lesions (Vulnology)*. 5th ed. Pavia: Editions CdG; 2019.
24. Murphy C, Atkin L, Swanson T, et al. Defying hard-to-heal wounds with an early antibiofilm intervention strategy: wound hygiene. *J Wound Care*. 2020;29(Sup3b):S1-S26. doi:10.12968/jowc.2020.29.Sup3b.S1.
25. World Union of Wound Healing Societies (WUWHS), Florence Congress, Position Document. Management of Biofilm. *Wounds International* 2016.
26. Swanson T, Ousey K, Haesler E, et al. IWII Wound Infection in Clinical Practice consensus document: 2022 update. *J Wound Care*. 2022;31(Sup12):S10-S21. doi:10.12968/jowc.2022.31.Sup12.S10.

-
27. Falanga V, Saap LJ, Ozonoff A. Wound bed score and its correlation with healing of chronic wounds. *Dermatol Ther.* 2006;19(6):383-390. doi:10.1111/j.1529-8019.2006.00096.x.